

## Comparative Assessment of Condylar Changes in Patients Treated with Twin Block Appliance: A Cone-Beam Computed Tomography Study

Vedavathi H. K<sup>1</sup>, Arora Chirag K.<sup>2</sup>

<sup>1,2</sup>Department of Orthodontics and Dentofacial Orthopedics, Vokkaligara Sangha Dental College and Hospital, Bengaluru, Karnataka

---

### Abstract

**Background:** The purpose of this study was to evaluate the condylar changes through cone beam computed tomography images in patients treated with twin block functional appliance.

**Material and Method:** In this study, CBCT of 30 patients who were treated with the Twin Block appliance were used. Pretreatment (T0) and Posttreatment (T1) condylar volume was compared on the 3D images. Angular measurements (Saddle angle, Gonial angle, ANB angle, Angle of Convexity and lower facial Height angle) and Linear Measurements (Na-Me, Co-Gn, CoR-CoL, CC-Gn) were also measured and compared by using 3D images. Differences between T0 and T1 were analyzed and compared with the use of paired 't' test and Wilcoxon signed rank test.

**Result:** Increase in Condylar volume, Gonial angle, Lower Facial Height angle, CoR-CoL, Co-Gn, CC-Gn and N-Me by 310.4mm<sup>3</sup>, 2.208°, 15.875°, 3.396mm, 4.65mm, 3.845mm, 7.667mm and decrease in Saddle angle, ANB angle and Facial Convexity 1.137°, 3.375° and 3.417° respectively.

**Conclusion:** Twin Block appliance therapy increases the condylar volume, Mandibular length, Intercondylar distance and CC-Gn, lower facial height angle, Gonial angle and Anterior facial height due to increases in the length of the condyle, upward and backward growth of the condyle and downward rotation of the mandible and decreases the Saddle angle, ANB angle and Facial Convexity by remodeling of the glenoid fossa and forward position of the mandible.

**Keywords:** Cone Beam Computed Tomography, Functional Appliance, Twin Block, Condyle, Temporomandibular Joint

---

### I. Introduction

The importance of beauty and attractiveness in today's society has been well established.<sup>1</sup> Patients with Class II malocclusions are referred mainly for esthetic enhancement as the increased overjet and unpleasant profile may lead to negative self-image in these patients. Class II malocclusion which comprises a group of specific skeletal, dental, and facial features, is one of the most common orthodontic problems, and it occurs in about one third of the population. Class II malocclusion is more common in whom mandibular retrognathism is a consistent finding.<sup>2</sup>

In the treatment modality of Class II malocclusion with mandibular retrognathism, different removable appliances (Activator, Bionator, Twin-Block, Frankel regulator, Twin Block etc.) or fixed appliances (Herbst Appliance, Mandibular advancement repositioning splint, Mandibular protraction appliance, Eureka Spring, Jasper Jumper, Churro Jumper, Mandibular anterior repositioning appliance, Functional Mandibular Advancer etc.) have been used to redirect the growth to correct skeletal discrepancy. Out of all the above-mentioned appliances, Twin Block is one of the most effective in controlling the mandibular plane angle and has the greatest long term effect on labial version of the mandibular incisors and high level of comfort and patient compliance than any other removable appliance.<sup>3-13</sup>

In orthodontic literature, adaptation of Temporomandibular joint (TMJ) following functional therapy has been envisaged by various techniques like lateral cephalograms<sup>14-16</sup>, orthopantomogram<sup>17</sup>, computed tomography scan<sup>18-19</sup>, and magnetic resonance imaging.<sup>20-21</sup> However, there are many constraints for the visualization of the TMJ using conventional techniques.<sup>22-27</sup> Cone-beam computed tomography produces more detailed images that minimize the distortion, gives high resolution and allows the formation of three-dimensional (3D) images in all three planes (sagittal, coronal, and axial).

Currently, CBCT has been frequently used in the precise measurement of dental and maxillofacial pathologies, orthodontic diagnosis and treatment plan, craniofacial morphology and airway assessment. In literature, there are also studies which reflect the use of CBCT for estimation of mandibular condylar volume.<sup>28-29</sup> In recent studies, they have compared the measurements from 2-dimensional (2D) cephalograms and 3D cone-beam computed tomography (CBCT). Lee et al.<sup>30</sup> concluded that for the assessment of surgical outcomes, image

fusion is a reliable method which is not affected by spatial or surgical changes. In the literature, it was determined that CBCT has been used to assess the condylar growth after functional appliance. However, few studies have focused on assessment of condylar response to functional appliance by the use of CBCT.

The purpose of this study was to evaluate the condylar changes treated by Twin block appliance through pretreatment and posttreatment CBCT images.

## **II. Materials and Methods**

Forty-eight CBCT images (24 pretreatment and 24 posttreatment) visiting the Department of Orthodontics were included in this study. All the subjects were informed about the procedures to be performed and signed informed consent was obtained from the parent/guardian. Twenty-four patients (11 male subjects with mean age of 12.82 years and 13 females subjects with mean age of 12.61 years) who fulfilled the selection criteria were included for this after the approval of the Ethical Committee of Vokkaligara Sangha Dental College and Hospital.

### **The Images Were Taken From The Patients Who Were Selected According To Following Criteria:**

- Growing patients
- Class II division 1 malocclusion with normal maxilla and retrognathic mandible
- Bilateral class II molar and canine relation
- Horizontal or average growth pattern
- Age Group 11-14 years (According to Hagg and Taranger- Stage MP3-FG and MP3-G)

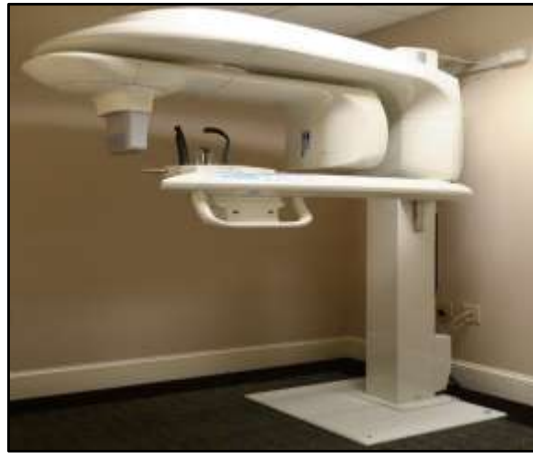All the patients were treated with Twin-Block functional appliance. Class I molar and canine relationship was obtained, and increased overjet was eliminated at the end of functional therapy. The average time for functional treatment was 7-9 months. Condylar response to the functional therapy was evaluated on CBCT images that had been taken before treatment (T0) and after functional therapy (T1). A full skull CBCT scan was taken before the insertion of the Twin Block to check for the position of the condyle, condylar volume, body of the mandible, length between two condylion, anterior facial height, gonial angle, saddle angle, lower facial height angle and facial convexity using KODAK 9000 3D Extraoral Imaging System (Carestream Health, Rochester, New York) (Fig.1).

Pretreatment and posttreatment images were taken while the patients were sitting in an upright position with the Frankfort horizontal plane parallel to the ground. They were instructed to breathe normally through the nose and to avoid swallowing during the scanning process. CBCT datasets were acquired by software with reconstruction slice thickness of 0.300 mm and 728 X 728 matrix. A single 270-degree rotation 20-second-high resolution scan was made with isotropic voxel size set at 0.300mm and 14 X 19 cm field of view. The raw images were exported into Digital Imaging and Communications in Medicine (DICOM). All landmark identifications and measurements were made using CS 3D Imaging Software (Carestream Health, Rochester, New York) software. (Fig.2)

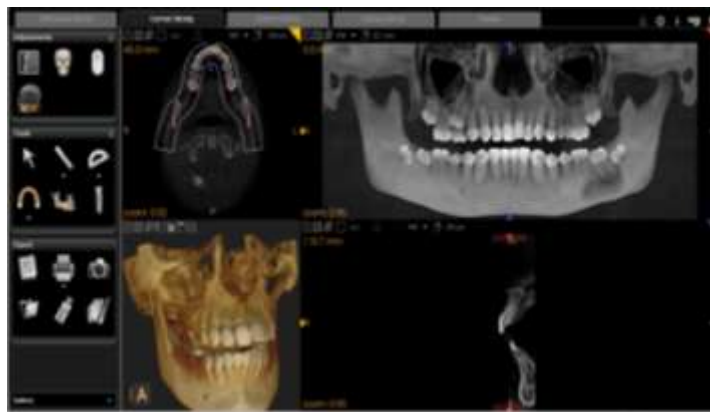
To carry out the measurements on CBCT scan, conventional oblique slicing and curved slicing was used. To carry out the measurement of the facial convexity, saddle angle, Gonial angle, Lower facial height angle Co-Gn, CC-Gn, and Na-Me oblique slicing was adjusted at 167.1 mm. Linear measurement like the distance between right and left condylion was obtained from curved slicing at 20.1 mm. (Fig.3) To obtain the lower facial height angle, saddle angle, ANB angle, Gonial angle, facial convexity, the oblique slicing was adjusted to 83.7 mm to get cleared picture of sphenoid bone. (Fig.4)

To measure the condylar volume, height of the condyle, length of the condyle and width of the condyle was obtained by custom slicing at 899 $\mu$ m. The condylar length was measured from the line extending from the posterior mandibular condyle point (PCo) to the anterior mandibular condyle point (ACo). Both these points are located 4 mm inferior to the superior mandible condyle (SCo) on either side of the condyle. Condylar width, which is the linear distance between the medial and lateral mandible poles, was measured in the coronal plane. Condylar height was measured as a perpendicular linear distance from superior mandible condyle (SCo) to a line constructed between the most inferior point of the sigmoid notch (InfSig) perpendicular to the tangent of the posterior surface of the ramus in the sagittal plane. (Fig.5)

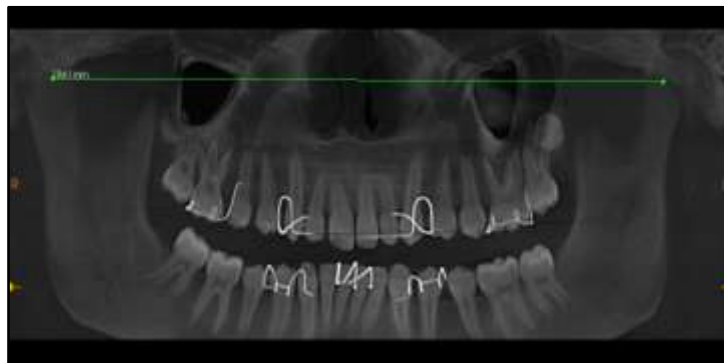
The data obtained was subjected to statistical analysis. Means, standard, errors, and standard deviations were tabulated, with the paired 't' test -calculated with the help of SPSS (Statistical Package for Social Science Software). The level of significance was set at  $p \leq 0.05$ .



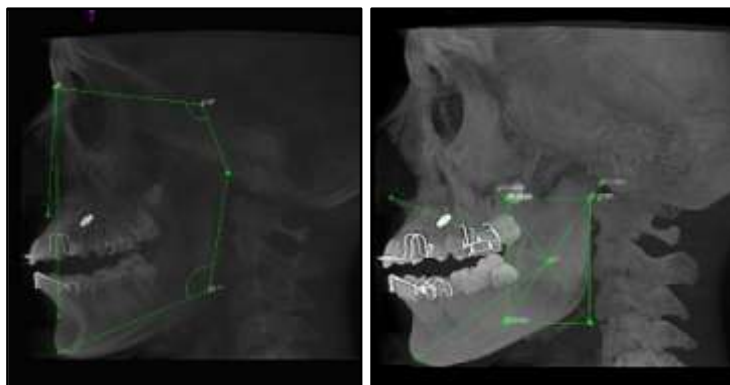
**Figure 1.** kodak 9000 3d extraoral imaging system



**Figure2.** CS 3D Imaging Software



**Figure 3.** linear measurement



**Figure4.**angular measurements

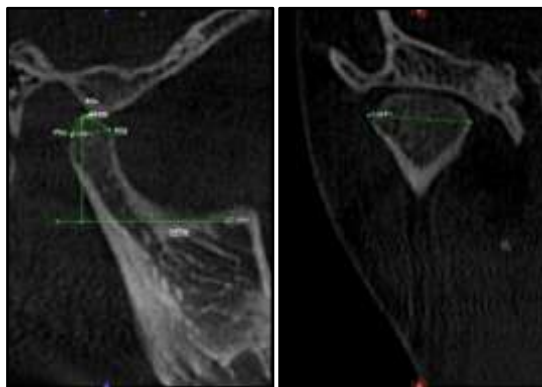


Figure 5. condylar volume

### III. Results

Means, standard deviations, and comparisons of the volumetric, angular, and linear measurements for pretreatment and posttreatment are given in Table 1. Evaluation of volumetric measurements revealed that condylar volume increased at both the left and right sides ( $p < 0.001$ ). Angular measurements showed a decrease in ANB angle, Saddle angle and Facial Convexity angle ( $p < 0.001$ ) and an increase in Gonial angle and lower facial height angle ( $p < 0.001$ ). In the evaluation of linear parameters, it was determined that CoR-CoL, CC-Gn, Co-Gn and Anterior facial height measurements increased significantly at both sides ( $p < 0.001$ ). Comparison of differences by sex was insignificant for all measurements ( $p < 0.001$ ).

Table 1: Descriptive Statistics of the Measurements With Results of Paired ‘t’ Tests

Measurements	T0		T1		Mean difference	P value
	Mean	SD	Mean	SD		
Left condyle volume, mm <sup>3</sup>	2719.02	119.24	3066.48	134.64	-347.456	<0.001
Right condyle volume, mm <sup>3</sup>	2563.74	121.54	2837.08	122.27	-273.338	<0.001
Saddle angle	123.16	4.92	122.03	4.98	1.137	<0.001
Gonial angle	120.83	7.14	123.04	6.08	-2.208	<0.001
ANB angle	6.33	1.61	2.96	1.37	3.375	<0.001
Facial convexity	5.08	1.93	1.67	0.81	3.417	<0.001
Lower facial height angle	32.29	4.67	48.17	4.20	-15.875	<0.001
Anterior facial height	107.28	8.78	114.95	8.29	-7.667	<0.001
CoR-CoL mm	189.28	15.70	192.68	15.82	-3.396	<0.001
CoR-Gn	98.57	5.69	102.75	5.45	-4.179	<0.001
CoL-Gn	96.53	5.76	101.65	5.44	-5.125	<0.001
CCR-Gn	88.96	7.89	93.25	7.96	-3.296	<0.001
CCL-Gn	89.53	7.69	92.93	7.97	-3.400	<0.001

### IV. Discussion

“What is beautiful is good” and beauty of the face is created by the well-balanced face. The attractiveness of the face depends on the balance between hard tissue, soft tissue and the dentoalveolar system. Any deviation from normal development of the stomatognathic system can lead to malocclusion. Class II malocclusion can be due to the maxillary excess, mandibular deficiency or a combination of both.

According to McNamara,<sup>2</sup> 60% of the Class II patients having mandibular deficiency need forward positioning or stimulation of favorable growth of the mandible. With more number of mandibular deficiencies in the Class II patient population, an effective means of enhancing the forward growth and development of the mandible is desirable. To bring about some changes in the posture, size and shape of the mandible, functional jaw orthopaedics can be applied during the treatment of Class II malocclusion with mandibular deficiency.

Twin block appliance was used in the present study as it has many advantages over other functional jaw orthopedics appliances. It is designed for full time wear, the functional inclines serve like natural dentition, vertical eruption of posterior teeth can be easily controlled, less obstructive during speech, lateral movements of the jaw and other oral functions. Also, the appliance design is simple over one piece appliance.

In the present study, growing children between the age of 12-14 years with a mean age of 12.70 years and in peak pubertal growth phase were selected. Baccetti et al<sup>31</sup> concluded that the optimal timing for functional appliance therapy is during or slightly after the onset of the pubertal peak (12 years, 11 months), resulting in greater skeletal contribution to the correction of the molar relation, significant increase in total mandibular length and ramus height, and more posterior direction of condylar growth. The placement of the

Twin Block appliance results in displacement of the condyle in the glenoid fossa which stimulates the growth of the condylar cartilage leading to changes in the TMJ.

Cephalometric and panoramic radiographs are widely used in orthodontic practice because of low cost, ease of use, availability and low radiation exposure. However, there are some demerits of the cephalometric radiograph which limits its use in the field of TMJ evaluation and anatomic superimposition. Validity of 2D imaging is doubtful as it depends on patients' head position and beam projection angle. Anatomic superimposition and magnification differences of the left and right sides that cause double border of the mandible on the radiograph are the other disadvantages of the conventional cephalometry.

3D Cone Beam Computed Tomography is one of the recent advances. In the evaluation of the craniofacial structures, CBCT is more reliable than conventional computed tomography because of lower radiation exposure. It is possible to scan the complete head within few seconds with an effective dose of 50 mSv with CBCT, while the conventional computed tomography uses 2000 mSv. Other advantages of CBCT are lower costs, increased accessibility to orthodontic practitioners, flexibility in the field of view and submillimeter spatial resolution. Bruno Frazao Gribel et al<sup>32</sup> concluded that CBCT craniometric measurements are accurate to subvoxel size and can be used as orthodontic diagnostic tool potentially. Hang Seo Park et al<sup>33</sup> concluded that 3D measurements are better than 2D lateral cephalogram wherein superimposition led to different angular and linear measurements. Hilgers et al<sup>34</sup> reported that CBCT measurements were significantly more reliable than lateral, posteroanterior and submentovertex cephalometric measurements.

Because of the above advantages of CBCT over 2D lateral cephalogram, it was used in the present study, to evaluate the skeletal changes in the condyle, angular measurements (saddle angle, gonial angle, ANB angle, facial convexity and lower facial height angle) and the linear measurements (CoR-CoL, Co-Gn, CC-Gn and Na-Me) following Twin Block therapy.

Many controversies exist regarding the effects produced by the functional appliances. Many studies showed that both skeletal and dentoalveolar changes results from functional appliances. With the recent advances in technology it is now possible to evaluate skeletal and dental changes quantitatively with the help of CBCT. In the present study, skeletal changes were evaluated which include condylar volume, angular measurements and linear measurements. CBCT of full skull was taken before and after Twin Block therapy and the results are discussed below.

The condyle is growth site of the mandible and plays an important role in the growth and development of the mandible. Two-dimensional sagittal slice was selected in which the condyle and glenoid fossa were clearly noticed. From this slice the condylar length was measured. The condylar length was measured from the line extending from the posterior mandibular condyle point (PCo) to the anterior mandibular condyle point (ACo). Both these points are located 4 mm inferior to the superior mandible condyle (SCo) on either side of the condyle. Condylar width, which is the linear distance between the medial and lateral mandible poles was measured in the coronal plane. Condylar height was measured as a perpendicular linear distance from superior mandible condyle (SCo) to a line constructed between the most inferior point of the sigmoid notch (InfSig) perpendicular to the tangent of the posterior surface of the ramus in the sagittal plane. CBCT measurements showed that condylar volume increased little more on left side than right side, which was not statistically significant. Mean value of right and left condylar volume showed increased in condylar volume by 310.4 mm<sup>3</sup>.

Saddle angle which is an angle formed between Nasion(N)-Sella(S)-Articulare(Ar) indicate the position of the glenoid fossa. CBCT measurements showed that saddle angle decreased after twin block therapy which indicates remodeling of the glenoid fossa in anterior and downward direction. Gonial angle is formed between the tangents to the posterior border of the mandibular ramus (Ar – Go) and inferior border of the body of the mandible (Go – Me). Gonial angle indicates the rotation of the mandible. CBCT showed increased Gonial angle which indicate the downward growth of the mandible. ANB angle evaluates the relationship of maxilla to mandible. If the ANB angle is more it indicates Class II skeletal pattern. CBCT measurements showed decreased ANB angle which indicate the correction of the Class II skeletal pattern by advancement of the mandible after Twin Block therapy. Facial Convexity measures the extent of protrusion or retrusion of the lower jaw, the relationship of the jaws to each other, the convexity of the maxilla and the inclination of the lower jaw. A negative angle is associated with the prognathic profile. In the present study, decrease in facial convexity was observed which indicated the forward positioning of the lower jaw. Lower facial height angle which is formed by the intersection of line from ANS to Xi point (located at the center of the ramus) and the corpus axis (Xi-Pm) remains constant with the age and change due to treatment mechanics. CBCT measurements showed increase in lower facial height angle which indicate the downward position of the mandible.

Anterior Facial Height (N-Me) results from vertical growth of the maxillary complex which descends 0.7mm per year; upper dentoalveolar height increase that is approximately 0.9mm per year and lower dentoalveolar increase that is 0.7mm per year. So, expected anterior vertical growth would be approximately 2.3 mm at the end of the one year. CBCT measurements of the present study showed increased anterior facial height due to downward rotation of the mandible. Right condylion to left condylion is the distance between two

condyles. CBCT measurements showed increase in the right to left condylion due to the forward and downward position of the condyle leads to the upward and backward growth of the condylar head. Center of the Cranium (CC- intersection of Ba-N plane and facial axis)-Gn indicate the direction of the growth of the chin. In the present study, CC-Gn increased indicate the downward growth of the mandible.Center of the Condyle (Co)-Gn indicate the direction of the growth of the chin. In the present study, Co-Gn increased indicating the downward growth of the mandible.

## V. Conclusion

- Twin Block Appliance therapy increases the condylar volume by stimulating the growth of the condyle in upward and backward direction.
- Twin Block Appliance therapy increases the intercondylar distance and mandibular length by stimulating the growth of the condyle in upward and backward direction.
- Twin Block Appliance therapy increases the Gonial angle and decreases the saddle angle due to the remodeling of the Glenoid fossa and forward position of the condyle.
- Twin Block Appliance therapy increases the lower facial height angle and anterior facial height due to downward rotation of the mandible.
- Twin Block Appliance therapy decreases ANB angle and facial convexity which correcting the class II malocclusion by forward growth of the mandible.
- Twin Block Appliance therapy increases the CC-Gn and Co-Gn due to increase the length of the mandible and forward positioning of the chin.

## References

- [1]. Little AC, Jones BC, DeBruine LM. Facial attractiveness: evolutionary based research. *Philosophical Transactions of the Royal Society B: Biological Sciences*. 2011 Jun 12;366(1571):1638-59.
- [2]. MCNAMARA JR JA. Components of Class II malocclusion in children 8-10 years of age. *The Angle orthodontist*. 1981 Jul;51(3):177-202.
- [3]. Tümer N, Gültan AS. Comparison of the effects of monoblock and twin-block appliances on the skeletal and dentoalveolar structures. *American journal of orthodontics and dentofacial orthopedics*. 1999 Oct 31;116(4):460-8.
- [4]. Schaefer AT, McNamara JA, Franchi L, Baccetti T. A cephalometric comparison of treatment with the Twin-block and stainless steel crown Herbst appliances followed by fixed appliance therapy. *American journal of orthodontics and dentofacial orthopedics*. 2004 Jul 31;126(1):7-15.
- [5]. Cozza P, Baccetti T, Franchi L, De Toffol L, McNamara JA. Mandibular changes produced by functional appliances in Class II malocclusion: a systematic review. *American Journal of Orthodontics and Dentofacial Orthopedics*. 2006 May 31;129(5):599-e1.
- [6]. Jena AK, Duggal R, Parkash H. Skeletal and dentoalveolar effects of Twin-block and bionator appliances in the treatment of Class II malocclusion: a comparative study. *American journal of orthodontics and dentofacial orthopedics*. 2006 Nov 30;130(5):594-602.
- [7]. Varlık SK, Gültan A, Tümer N. Comparison of the effects of Twin Block and activator treatment on the soft tissue profile. *The European Journal of Orthodontics*. 2008 Apr 1;30(2):128-34.
- [8]. Siara-Olds NJ, Pangrazio-Kulbersh V, Berger J, Bayirli B. Long-term dentoskeletal changes with the Bionator, Herbst, Twin Block, and MARA functional appliances. *The Angle orthodontist*. 2010 Jan;80(1):18-29.
- [9]. Thiruvkatachari B, Sandler J, Murray A, Walsh T, O'Brien K. Comparison of Twin-block and Dynamax appliances for the treatment of Class II malocclusion in adolescents: A randomized controlled trial. *American Journal of Orthodontics and Dentofacial Orthopedics*. 2010 Aug 31;138(2):144-e1.
- [10]. Fernandes AF, Brunharo IH, Quintão CC, Costa MG, de Oliveira-Costa MR. Effectiveness of twin blocks and extraoral maxillary splint (Thurrow) appliances for the correction of Class II relationships. *World journal of orthodontics*. 2010 Sep 1;11(3).
- [11]. Baysal A, Uysal T. Soft tissue effects of Twin Block and Herbst appliances in patients with Class II division 1 mandibular retrognathia. *The European Journal of Orthodontics*. 2011 Feb 28;cjq187.
- [12]. Ehsani S, Nebbe B, Normando D, Lagravere MO, Flores-Mir C. Dental and skeletal changes in mild to moderate Class II malocclusions treated by either a Twin-block or Xbow appliance followed by full fixed orthodontic treatment. *The Angle orthodontist*. 2015 Jan 21;85(6):997-1002.
- [13]. Giuntini V, Vangelisti A, Masucci C, Defraia E, McNamara Jr JA, Franchi L. Treatment effects produced by the Twin-block appliance vs the Forsus Fatigue Resistant Device in growing Class II patients. *The Angle Orthodontist*. 2015 Mar 18;85(5):784-9.
- [14]. Panchez H, Ruf S, Kohlhas P. "Effective condylar growth" and chin position changes in Herbst treatment: a cephalometric roentgenographic long-term study. *American journal of orthodontics and dentofacial orthopedics*. 1998 Oct 31;114(4):437-46.
- [15]. Ruf S, Baltromejus S, Panchez H. Effective condylar growth and chin position changes in activator treatment: a cephalometric roentgenographic study. *The Angle orthodontist*. 2001 Feb;71(1):4-11.
- [16]. Panchez H, Fischer S. Amount and direction of temporomandibular joint growth changes in Herbst treatment: a cephalometric long-term investigation. *The Angle Orthodontist*. 2003 Sep;73(5):493-501.
- [17]. Dixon DC. Radiographic diagnosis ofttemporomandibular disorders. In *Seminars in orthodontics* 1995 Dec 31 (Vol. 1, No. 4, pp. 207-221). WB Saunders.
- [18]. Cohlmiä JT, Ghosh J, Sinha PK, Nanda RS, Currier GF. Tomographic assessment of temporomandibular joints in patients with malocclusion. *The Angle Orthodontist*. 1996 Feb;66(1):27-36.
- [19]. Arici S, Akan H, Yakubov K, Arici N. Effects of fixed functional appliance treatment on the temporomandibular joint. *American Journal of Orthodontics and Dentofacial Orthopedics*. 2008 Jun 30;133(6):809-14.
- [20]. Chintakanon K, Sampson W, Wilkinson T, Townsend G. A prospective study of Twin-block appliance therapy assessed by magnetic resonance imaging. *American Journal of Orthodontics and Dentofacial Orthopedics*. 2000 Nov 30;118(5):494-504.
- [21]. Arat ZM, Gökalp H, Erdem D, Erden I. Changes in the TMJ disc-condyle-fossa relationship following functional treatment of skeletal Class II Division 1 malocclusion: a magnetic resonance imaging study. *American Journal of Orthodontics and Dentofacial Orthopedics*. 2001 Mar 31;119(3):316-9.

- [22]. Gribel BF, Gribel MN, Frazão DC, McNamara Jr JA, Manzi FR. Accuracy and reliability of craniometric measurements on lateral cephalometry and 3D measurements on CBCT scans. *The Angle orthodontist*. 2011 Jan;81(1):26-35.
- [23]. Park CS, Park JK, Kim H, Han SS, Jeong HG, Park H. Comparison of conventional lateral cephalograms with corresponding CBCT radiographs. *Imaging science in dentistry*. 2012 Dec 1;42(4):201-5.
- [24]. Markic G, Müller L, Patcas R, Roos M, Lochbühler N, Peltomäki T, Karlo CA, Ullrich O, Kellenberger CJ. Assessing the length of the mandibular ramus and the condylar process: a comparison of OPG, CBCT, CT, MRI, and lateral cephalometric measurements. *The European Journal of Orthodontics*. 2014 Aug 23:cju008.
- [25]. Pittayapat P, Bornstein MM, Imada TS, Coucke W, Lambrechts I, Jacobs R. Accuracy of linear measurements using three imaging modalities: two lateral cephalograms and one 3D model from CBCT data. *The European Journal of Orthodontics*. 2014 Aug 25:cju036.
- [26]. Al-Saleh MA, Jaremko JL, Alsufyani N, Jibri Z, Lai H, Major PW. Assessing the reliability of MRI-CBCT image registration to visualize temporomandibular joints. *Dentomaxillofacial Radiology*. 2015 Mar 31;44(6):20140244.
- [27]. Ludlow JB, Gubler M, Cevidane L, Mol A. Precision of cephalometric landmark identification: cone-beam computed tomography vs conventional cephalometric views. *American Journal of Orthodontics and Dentofacial Orthopedics*. 2009 Sep 30;136(3):312-e1.
- [28]. Al-koshab M, Nambiar P, John J. Assessment of condyle and glenoid fossa morphology using CBCT in South-East Asians. *PLoS one*. 2015 Mar 24;10(3): e0121682.
- [29]. Yildirim E, Karacay S, Erkan M. Condylar response to functional therapy with Twin-Block as shown by cone-beam computed tomography. *The Angle Orthodontist*. 2014 Apr 9;84(6):1018-25.
- [30]. Lee JH, Kim MJ, Kim SM, Kwon OH, Kim YK. The 3D CT superimposition method using image fusion based on the maximum mutual information algorithm for the assessment of oral and maxillofacial surgery treatment results. *Oral surgery, oral medicine, oral pathology and oral radiology*. 2012 Aug 31;114(2):167-74.
- [31]. Baccetti T, Franchi L, Toth LR, McNamara JA. Treatment timing for Twin-block therapy. *American Journal of Orthodontics and Dentofacial Orthopedics*. 2000 Aug 31;118(2):159-70.
- [32]. Gribel BF, Gribel MN, Frazão DC, McNamara Jr JA, Manzi FR. Accuracy and reliability of craniometric measurements on lateral cephalometry and 3D measurements on CBCT scans. *The Angle orthodontist*. 2011 Jan;81(1):26-35.
- [33]. Park CS, Park JK, Kim H, Han SS, Jeong HG, Park H. Comparison of conventional lateral cephalograms with corresponding CBCT radiographs. *Imaging science in dentistry*. 2012 Dec 1;42(4):201-5.
- [34]. Hilgers ML, Scarfe WC, Scheetz JP, Farman AG. Accuracy of linear temporomandibular joint measurements with cone beam computed tomography and digital cephalometric radiography. *American journal of orthodontics and dentofacial orthopedics*. 2005 Dec 31;128(6):803-11.